

INTRODUCTION

Solea laser-assisted periodontal surgery is effective for treating moderate to severe periodontal disease,¹ offering efficient, minimally invasive procedures with minimal post-op pain and fast healing.^{2,3} This case highlights Solea's ability to achieve elevated clinical outcomes and improve patient experience.³

CLINICAL CHALLENGE

A 53-year-old patient came in for an emergency consultation due to an acute periodontal crisis, fearing the potential loss of a tooth. The patient presented with advanced periodontal disease characterized by:

- Extensive calculus and plaque accumulation
- Loss of attached gingiva
- Widened periodontal ligament (PDL)
- Significant bone loss

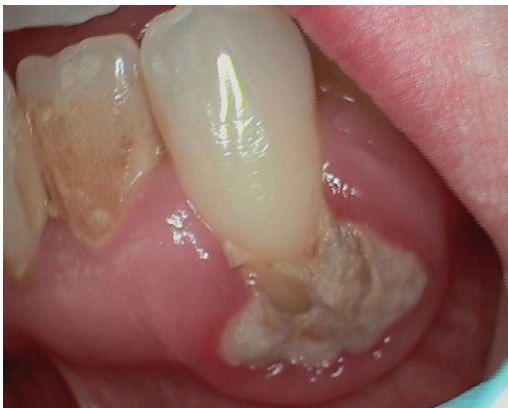Upon examination, the patient was diagnosed with Acute Periodontitis. Given the severity of the condition, immediate intervention was necessary.

CLINICAL OBJECTIVES

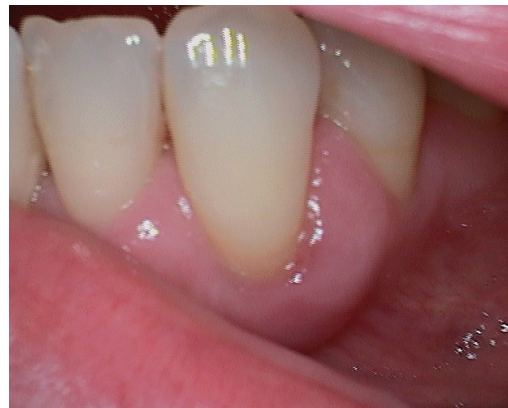The primary goal was to restore periodontal health by thoroughly debriding the affected area, scaling, and root planing to remove plaque and calculus using a minimally invasive method.

SOLEA PROCEDURE DETAILS

The patient was anesthetized with 1 carpule of Septocaine infiltration. The Solea laser-assisted closed flap periodontal surgery allowed for deep scaling and root planing. Four packets of Arrestin were placed to combat bacterial infection. The use of the Solea laser significantly reduced the procedure time, completing the surgery in 15 minutes without the need for sutures. In contrast, traditional methods would have required at least an hour and complex suturing.



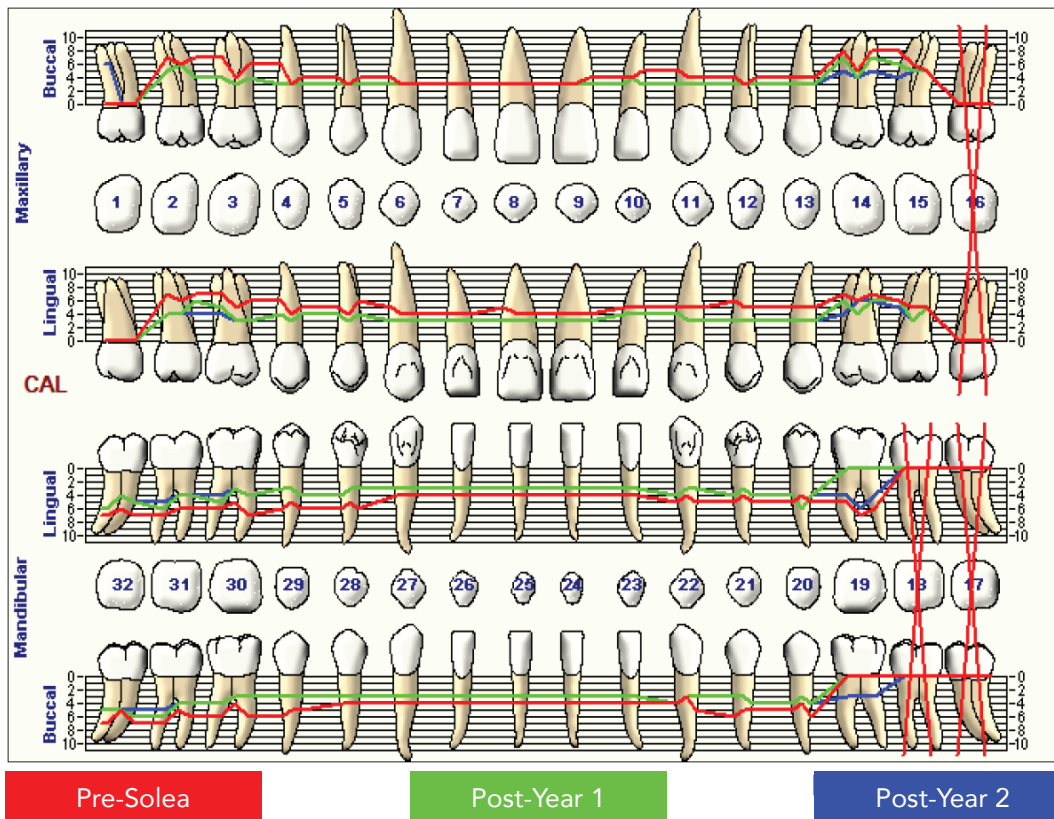
Pre-Op



Post-Year 1

CLINICAL OUTCOMES

Date	1	2	3	4	5	6	7	8	9	10	11	12	13	14	15
B Post-Year 2	6	5 6 4	4 3 4	3 3 3	3 3 3	3 3 3	3 3 3	3 3 3	3 3 3	3 4 3	3 3 3	3 3 3	3 3 3	5 4 5	4 5 5
Post-Year 1		5 6 4	4 3 4	3 3 3	3 3 3	3 3 3	3 3 3	3 3 3	3 3 3	3 4 3	3 3 3	3 3 3	3 3 3	7 4 7	6 5 5
Pre-Solea		7 6 7	7 4 6	6 3 4	4 3 4	4 3 3	3 3 3	3 3 3	3 3 4	4 4 5	5 4 4	4 3 4	4 4 4	8 5 8	8 6 5
L Post-Year 2		4 4 4	4 3 3	4 3 4	4 3 4	3 3 3	3 3 3	3 3 3	3 3 3	4 4 4	4 3 3	3 3 3	3 3 3	4 6 6	5 3 5
Post-Year 1		4 4 6	5 3 3	4 3 4	4 3 4	3 3 3	3 3 3	3 3 3	3 3 3	4 4 4	4 3 3	3 3 3	3 3 3	6 4 6	6 3 5
Pre-Solea		7 6 7	7 5 6	6 4 5	5 4 6	5 4 4	4 4 4	5 4 4	4 4 4	5 5 5	5 5 5	6 5 5	5 5 5	7 6 7	6 5 5
L Post-Year 2	6 4 5	5 4 4	4 3 4	3 3 4	4 3 3	3 3 3	3 3 3	3 3 3	3 3 3	3 3 3	4 3 3	4 3 4	4 6 4	4 6 4	
Post-Year 1	6 4 5	6 4 4	5 3 4	3 3 4	4 3 3	3 3 3	3 3 3	3 3 3	3 3 3	3 3 3	4 3 3	4 3 4	4 6 4		
Pre-Solea	7 6 7	7 6 6	6 5 7	6 5 6	6 5 6	4 4 4	4 4 4	4 4 4	4 4 4	4 4 4	5 4 5	5 4 5	5 4 5	5 7 6	
B Post-Year 2	5 5 5	5 4 4	4 3 3	3 3 3	3 3 3	3 3 3	3 3 3	3 3 3	3 3 3	3 3 3	4 3 3	3 3 4	4 3 4	3 3 3	
Post-Year 1	5 5 6	6 4 4	4 3 3	3 3 3	3 3 3	3 3 3	3 3 3	3 3 3	3 3 3	3 3 3	4 3 3	3 3 4	4 3 4		
Pre-Solea	7 5 7	7 5 6	6 4 6	6 5 5	4 4 4	4 4 4	4 4 4	4 4 4	4 4 4	4 4 4	4 3 5	6 5 5	5 4 6		
	32	31	30	29	28	27	26	25	24	23	22	21	20	19	18



Summary Data Comparison

Date	Bleeding Teeth	Bleeding Sites	Suppuration Teeth	Suppuration Sites	Furcation Teeth	Furcation Sites	Mobility Teeth	PD > Alert Teeth	PD > Alert Sites	CAL < 0 Teeth	CAL < 0 Sites	CAL 1-3 Teeth	CAL 1-3 Sites	CAL 4-5 Teeth	CAL 4-5 Sites	CAL 6+ Teeth	CAL 6+ Sites
Post-Year 2	0	0	0	0	0	0	0	18	61	0	0	24	109	17	53	6	7
Post-Year 1	0	0	0	0	0	0	0	16	57	0	0	23	106	16	43	6	13
Pre-Solea	0	0	0	0	0	0	0	28	151	0	0	8	14	27	106	15	45

CLINICAL OUTCOMES CONTINUED

The closed flap procedure with Solea resulted in minimal bleeding and substantially less post-operative pain compared to conventional open flap surgery. Remarkably, the healing time was reduced to just one week compared to six weeks using traditional methods. No pain or swelling noted at the one-week post-operative check.

Post-Operative Recovery: The patient exhibited excellent healing with healthy, pink, and stippled gingiva. There were no signs of erythema, edema, or bleeding on probing.

Periodontal Probing: Probing depths in the treated area decreased from 5-6 mm to 3-4 mm, indicating significant improvement. Additionally, there was a noticeable increase in gingival height and bone formation, which is an unprecedented result in similar cases.

Patient Compliance: The patient's compliance improved dramatically due to reduced pain and swelling, contributing to better overall tissue response and periodontal health maintenance over the two years following the procedure.

CONCLUSION

Using the Solea laser to treat this advanced case of periodontitis not only saved the patient's tooth but also achieved exceptional periodontal healing, including increased gingival height and new bone formation. The patient has maintained periodontal health for over two years post-treatment, with improved esthetics and significantly reduced pain. This case underscores the advantages of the Solea laser in delivering superior clinical outcomes and an elevated patient experience, particularly in cases that would typically be referred to a specialist.



Expand your services and elevate patient care by providing in-pocket minimally invasive periodontal therapy with **SOLEA PERIOGUIDE** (next generation *Ultraguide*). This application on the Solea® All-Tissue Laser enables you to deliver safe, effective and efficient laser periodontal treatments with minimal bleeding, sutures, and post-operative pain.^{2,3} With Solea Perioguide, your patients can receive exceptional care for their moderate to severe periodontitis from a dentist they know and trust.¹

» COMING SOON! Contact your local Convergent Dental Representative for more details or email us at perioguide@convergentdental.com

1. Nevins, Myron et al. "Human Clinical and Histologic Evaluations of Laser-Assisted Periodontal Therapy with a 9.3- μ m CO₂ Laser System." The International journal of periodontics & restorative dentistry vol. 40,2 (2020): 203-210. doi:10.11607/prd.4616.

2. Based on report of 1000 procedures performed by Solea users. Documentation on file. 3. Based on 2022 Annual Survey of Solea users. Documentation on file.